

# Extended Liver Resection and Hepatic Ischemia in Pigs: A New, Potentially Reversible Model to Induce Acute Liver Failure and Study Artificial Liver Support Systems

R. Ladurner<sup>a</sup> B. Hochleitner<sup>a</sup> S. Schneeberger<sup>a</sup> U. Barnas<sup>b</sup> A. Krismer<sup>c</sup>  
A. Kleinsasser<sup>c</sup> F. Offner<sup>d</sup> I. Königsrainer<sup>a</sup> R. Margreiter<sup>a</sup> A. Königsrainer<sup>a</sup>

Departments of <sup>a</sup>General and Transplant Surgery, <sup>b</sup>Neurosurgery, and <sup>c</sup>Anesthesiology and Critical Care Medicine, Innsbruck University Hospital, Innsbruck, and <sup>d</sup>Department of Pathology, Academic Teaching Hospital Feldkirch, Feldkirch, Austria

## Key Words

Hepatic ischemia · Extended liver resection · Liver failure

## Abstract

**Background:** Extended hepatectomy is a valid model for the study of acute liver failure. Since the porcine liver is comparable in size, morphology and anatomy to the human liver, we describe a technique employing hepatic ischemia and extended liver resection to induce acute liver failure in a porcine model as a means of studying bioartificial liver support. **Method:** A subtotal (75–80% resection) extended left hepatectomy was performed in 7 pigs after 60 min warm ischemia of the future remnant liver. After resection, the animals were given the best supportive care and observed until death. **Results:** All animals died within 18–48 h, none as a result of surgical complications. Gross appearance of the liver showed severe steatosis of the right lateral lobe, and histology revealed severe coagulative necrosis of the whole lobule. **Conclusion:** This technique of extended liver resection after hepatic ischemia in the porcine model may be useful for studies of potentially reversible acute liver failure and experimental bioartificial support.

## Introduction

Acute liver failure is a rare clinical syndrome associated with mortality rates of up to 70–80% [1, 2]. A number of conditions such as viral hepatitis, acetaminophen toxicity and idiosyncratic drug reactions, to name but a few, can cause sudden severe liver dysfunction, which ultimately triggers a multiorgan response. The current treatment for acute liver failure is not satisfactory. Although the liver has a high regenerative capacity, orthotopic liver transplantation often remains the therapy of choice on balance. However, the shortage of donor organs means that many of these patients die before receiving a liver graft. Fortunately, encouraging results have been reported for recently developed bioartificial liver support systems, which can temporarily take over the complex function of the liver and provide a bridge to transplantation or spontaneous recovery.

Domestic swine are commonly used in experimental surgery because of the numerous similarities between porcine and human anatomy and physiology [3]. Moreover, the size match with human organs makes results of experimental surgical procedures more relevant as compared to small animal models. The present study examines the technique of prolonged hepatic ischemia fol-

Copyright © 2005 S. Karger AG, Basel

## KARGER

Fax +41 61 306 12 34  
E-Mail [karger@karger.ch](mailto:karger@karger.ch)  
[www.karger.com](http://www.karger.com)

© 2005 S. Karger AG, Basel  
0014-312X/05/0376-0365\$22.00/0

Accessible online at:  
[www.karger.com/esr](http://www.karger.com/esr)

Ruth Ladurner, MD  
Department of General and Transplant Surgery, University Hospital Tübingen  
Hoppe-Seyler-Strasse 3, DE-72076 Tübingen (Germany)  
Tel. +49 7071 29 80341, Fax +49 7071 29 4934  
E-Mail [ruth.ladurner@med.uni-tuebingen.de](mailto:ruth.ladurner@med.uni-tuebingen.de)

lowed by extended liver resection to induce acute liver failure in a porcine model for use in experimental bioartificial liver support.

## Materials and Methods

The project was approved by the Austrian Federal Animal Investigation Committee, and animals were handled in accordance with the National Institutes of Health guidelines. The study was conducted using 7 healthy, 6- to 8-week-old German landrace pigs weighing 25–35 kg.

**Anesthesia.** The animals were fasted overnight but had free access to water. They were premedicated with azaperone (4 mg/kg intramuscularly) and atropine (0.01 mg/kg intramuscularly) 1 h before surgery, and anesthesia was induced with propofol (2–4 mg/kg intravenously). After orotracheal intubation lungs were ventilated in a volume-controlled mode (Evita 4, Dräger, Lübeck, Germany) with a FIO<sub>2</sub> of 0.4 and a tidal volume of 10 ml/kg at 18 breaths/min. Respiratory rate was then adjusted to achieve a PaCO<sub>2</sub> between 35 and 40 Torr. Anesthesia was maintained with propofol (6–8 mg/kg/h) and piritramide (30–45 mg). Ringer's solution (6 ml/kg/h) and a 3% gelatine solution (4 ml/kg/h) were administered continuously. During parenchymal transection, blood loss was compensated with whole blood from donor pigs (median 300 ml, range 250–600 ml). The donor pigs were from the same brood and a compatibility test (bed-side test) was performed prior to transfusion. Before surgery, the pigs received a single shot of antibiotic prophylaxis with amoxicillin/clavulanic acid (6–8 mg/kg intravenously). A standard lead II electrocardiogram was used to monitor cardiac rhythm. In addition, oxygen saturation, pulse rate, arterial blood pressure and end-tidal carbon dioxide were monitored throughout the procedure. The depth of anesthesia was judged from blood pressure and heart rate. If cardiovascular variables indicated a reduced depth of anesthesia, additional propofol and piritramide was given. Body temperature was maintained between 38 and 39°C by means of a heating blanket. A 7-Fr catheter was percutaneously and in some cases surgically placed into the iliac artery for blood sampling and blood pressure measurements. Another 7-Fr catheter was placed in the vena cava superior to measure central venous pressure and administer drugs.

**Intracranial Pressure Measurement.** For intermittent measurement of intracranial pressure during acute liver failure, a hole was drilled through the frontal bone and a probe inserted in the epidural space. The probe was saline-filled and connected to a pressure transducer after zero adjustment.

**Experimental Liver Resection.** The pig was placed in a supine position and the abdomen opened through a complete midline laparotomy. A urinary catheter was inserted through a small cystotomy, blocked and fixed with a 4-0 vicryl purse-string suture to control diuresis. Dissection started with a transverse incision of the peritoneum at the liver hilum to expose the left hepatic duct, draining both the left medial and left lateral lobes. The cystic duct and the right anterior duct, draining the right medial segments, were isolated and divided without narrowing the lumen of the right posterior duct, draining the right lateral and caudate lobes. Then, the arterial branches for the left and both median lobes crossing the portal vein anteriorly were dissected, divided and ligated with 4-0 vicryl. After isolation of the portal branches, the hilar structures of

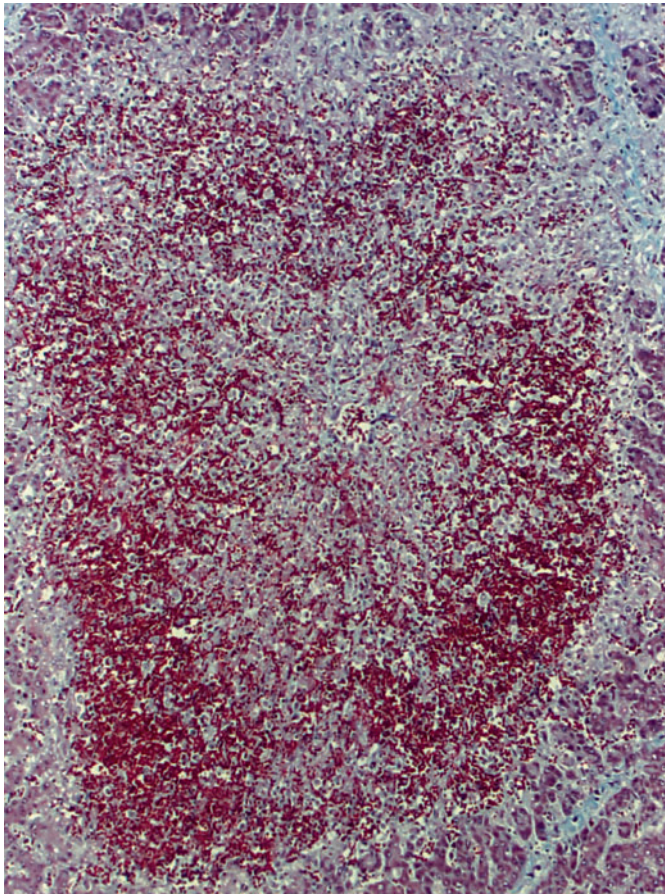
the future remnant right lateral segments and caudate lobe were clamped for 60 min to induce warm ischemia. Completeness of inflow occlusion was confirmed by Doppler ultrasound. After releasing the clamp, portal branches to the right median segment and left lobe were severed and both ends closed with a running 5-0 monofilament suture to prevent narrowing of the right lateral portal branch. Once dissection of the liver hilum was completed, discoloration identified the resection line between the right lateral and right medial lobe. The translucent falciform ligament was cut down to the infradiaphragmatic vena cava and hepatic veins were identified. Subsequently, the left triangular ligament and the lesser omentum were divided so as to completely mobilize the left liver lobes. Thereafter, a clamp was placed on the fissure between right medial and right lateral lobe. After resection of the right median and the left lobes the clamp was secured with a running 2-0 vicryl mattress suture. Care was taken not to compromise the caval or hepatic veins draining the right lateral segments. Parenchymal transection was usually completed within 15 min. During this phase, one to three units of blood, harvested from donor pigs, were given. Residual bleeding from the thin parenchymal layer covering the vena cava was controlled with 5-0 sutures. Bile leaks were suture-ligated. Minor oozing was finally controlled with fibrin sealing (Tissucol<sup>®</sup>, Baxter, The Netherlands and Glubran<sup>®</sup>, Comesa, Austria) and collagen fleece (Tachokomb<sup>®</sup>, Nykomed, Austria). After placing one silicone drain the abdomen was closed in layers with running sutures.

Following surgery, the animals were turned onto their right side and observed under optimal anesthesiological conditions including exact monitoring of hemodynamic parameters, liver function, diuresis and intracranial pressure until their spontaneous death. After death, the animals were carefully examined to identify surgical complications, and tissue samples from the remnant liver were excised for histological examination.

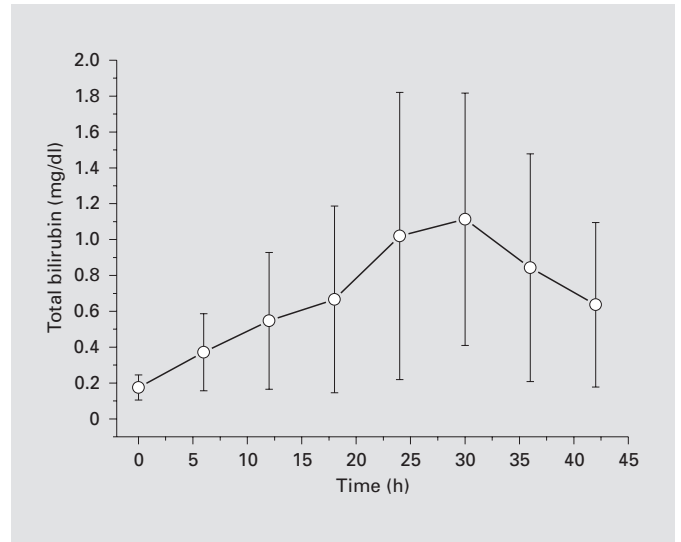
## Results

The described technique proved to be simple and reproducible. None of the animals died because of technical failure, but died from presumed liver failure within 18 and 48 hours of resection and hepatic ischemia. The gross appearance of the liver showed severe fatty degeneration with histological diffuse coagulative necrosis of the entire lobules with a large number of infiltrating polymorphonuclear leukocytes in the sinuses (fig. 1).

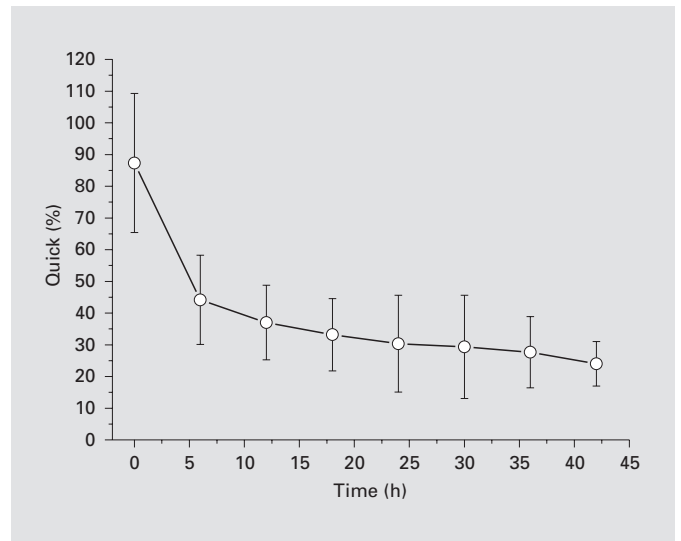
The preoperative and serial postoperative measurements of blood bilirubin, prothrombin time (Quick) and aspartate transaminase (AST) are given in figures 2–4. The bilirubin was elevated immediately postoperatively and reached the highest levels between 25 and 30 h after resection. A slow decrease was seen again in two animals dying 45 and 48 h after operation. The mean prothrombin time showed a significantly decrease in the first 5 h after surgery and remained low during the observation time, underlining liver failure. The aspartate transaminase increased significantly in the first 12 h after resection



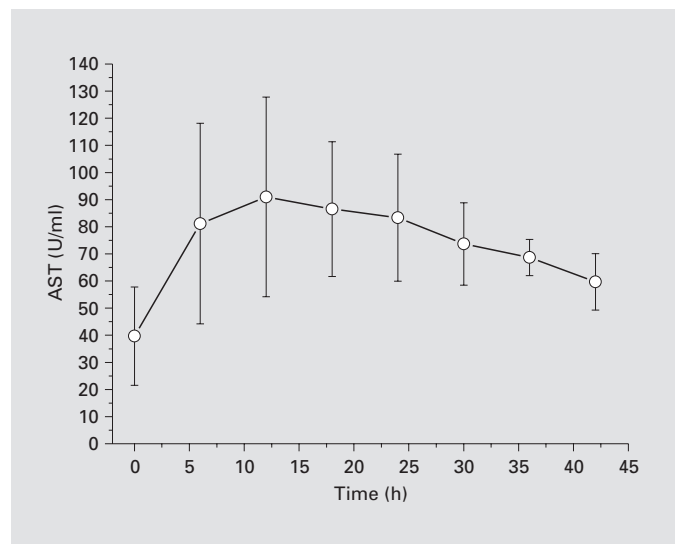
**Fig. 1.** Light microscopy using trichrome staining. Severe, diffuse necrosis of the hepatic lobule with a large number of infiltrating polymorphonuclear leukocytes and venous and sinusoidal congestion.



**2**



**3**

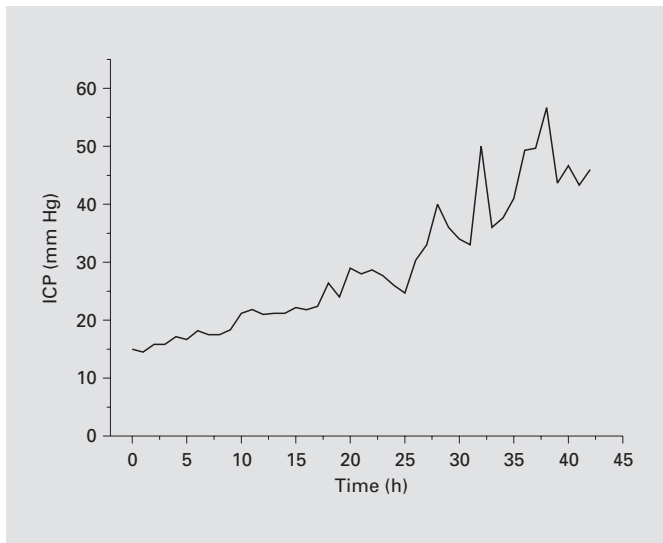


**4**

**Fig. 2.** Average bilirubin postoperatively. Values are given as means  $\pm$  SD.

**Fig. 3.** Average prothrombin time (Quick). Values are given as means  $\pm$  SD.

**Fig. 4.** Average aspartate transaminase. Values are given as means  $\pm$  SD.



**Fig. 5.** Mean values of intracranial pressure.

compared with the pre-operative measurements and higher levels persisted throughout the entire observation period. Nevertheless, neither aspartate, alanine transaminase,  $\gamma$ -glutamyl transferase nor alkaline phosphatase showed levels as expected in acute liver insufficiency. A possible reason is the lack of viable liver tissue after extended liver resection. Ammonia levels on the other hand increased continuously and reached the highest levels at the time of death (median 151, range 67–553 pmol/l). Similarly, renal function deteriorated in the postoperative period from median 1.24 mg/dl (range 0.97–1.76 mg/dl) immediately after hepatic ischemia and resection to 1.46 mg/dl (range 1.09–2.17 mg/dl) 12 h later. In the 2 animals that died after 45 and 48 h creatinine levels increased to 1.31 and 2.55 mg/dl, respectively.

Measurement of intracranial pressure (fig. 5) showed an initial constant increase of intracranial pressure in the first 18 h, becoming more rapid thereafter with mean levels between 56.7 and 47.7 mm Hg in the last hours before death.

## Discussion

To study acute liver failure and to evaluate the efficacy and safety of artificial and bioartificial liver support systems, several different animal models have been described, achieving hepatic failure through intoxication, infection, ischemia, or resection of the liver [4]. In con-

trast to methods using hepatic toxins, initiation of liver damage in surgical models is precisely defined and is not associated with tissue injury or inflammation [5, 6]. On the other hand, in ischemia models of complete or graded devascularization liver failure can be complicated by toxic liver syndrome with strong individual differences in tolerance to ischemia. In such models reproducibility is also difficult to achieve. Several investigators have therefore used models of total hepatectomy, representing the loss of all functional liver tissue [7]. From the surgical point of view, hepatectomy is technically more easily to perform than hepatic resection, but the major disadvantage of the model is the lack of spontaneous liver regeneration. Models of subtotal hepatic resection require high surgical skills and animal-specific anatomical knowledge, allowing spontaneous tissue regeneration with the advantage of potential reversibility of hepatic failure.

The pig is a useful experimental model for such investigation of liver surgery techniques because of its similarities to the human liver in terms of size, morphology and physiology. Furthermore, the segmental anatomy has proved to be similar to that of the human, as described by Couinaud [3, 8]. In addition, the lobular nature of the porcine liver makes anatomical resection easier. There are, however, certain anatomical differences that influence surgical technique. The intraparenchymal position of the inferior vena cava within the caudate lobe renders resection of the right lobe, which is next to the caudate lobe, technically demanding. If the right lateral lobe, as in our study, is to remain intact, attention has to be paid to the right posterior bile duct, which crosses behind the left portal branch and can be easily damaged during dissection and ligation of the left portal vein or the hepatic ducts draining all lobes that are to be resected [3]. Moreover, the hepatic veins, supplying the left lateral, the left medial, the right medial and the right lateral lobes with four main branches, and the vein draining segment I directly into the inferior vena cava are extremely thin-walled and fragile. Finally, there is a marked difference in the relative volume of the segments as compared with those in humans [9, 10], with the right lateral segment comprising about 20–25% of the total liver volume.

In further experiments [11], we studied hemodynamic and liver regeneration after resection of an average of 75% of liver volume. The regeneration rate of the remaining right lateral segment and segment I was 3.2 after the first postoperative week. The pigs tolerated extended hepatic resection well, thus the reason why in the herein described study a part from reduction of liver tissue by a 75% hepatectomy liver failure was induced by 60 min warm isch-

emia of the remnant liver, allowing potentially reversibility of hepatic failure while using liver support systems.

Nevertheless the pig liver is remarkably tolerant to normothermic ischemia, a finding reported previously by Nordlinger et al. [12], who found no significant increase in hepatic enzyme release in pig livers after 90 min of ischemia and subsequent reperfusion. Furthermore, human livers can survive ischemia periods of more than 60 minutes, although this is associated with significant morbidity [12, 13]. However, most animal studies on vascular occlusion of the liver have not included liver resection and studies on extended liver resection were not associated with hepatic ischemia [14].

The most important effect of temporary vascular occlusion of the right lateral lobe consisted of ischemia and reperfusion injury during clamping and recirculation after declamping. During reperfusion, additional liver injury is added to damage already sustained during ischemia and further aggravated in our study by subsequent

extended liver resection. Since, as with other animals [15, 16], the pig will not tolerate total clamping of the portal vein, after dissection of the arterial supply to the left hemiliver and right medial lobe, the main and the left portal trunk were left open to prevent splanchnic congestion during hilus occlusion of the right lateral lobe. As a consequence, a portocaval shunt recommended by others during prolonged hepatic pedicle clamping [17, 18] was not necessary. After releasing the clamp, the portal vein structures for the left and right medial lobes were dissected and ligated and the lobes (75–80% resection) rapidly resected. Thus, all remaining liver tissue was made ischemic and then reperfused.

In conclusion, the described technique of extended liver resection with 60 min clamping of the future remnant liver segments in the pig represents a well-reproducible and reliable model of acute liver failure in a large animal model allowing reversibility, that can be applied to test the safety and efficacy of liver support systems.

## References

- 1 Ostapowicz G, Lee WM: Acute hepatic failure: a Western perspective. *J Gastroenterol Hepatol* 2000;15:467–469.
- 2 Lee WM: Acute liver failure. *N Engl J Med* 1993;329:1862–1872.
- 3 Court FG, Wemyss-Holden SA, Morrison CP, Teague BD, Laws PE, Kew J, Dennison AR, Maddern GJ: Segmental nature of the porcine liver and its potential as a model for experimental hepatectomy. *Br J Surg* 2003;90:440–444, doi: 10.1002/bjs.2003.4053.
- 4 Frühauf NR, Kaiser GM, Nossler SA, Bader A, Oldhafer KJ: Large animal models for testing bioartificial liver support systems. *Biomed Sci Instrum* 2001;37:511–516.
- 5 Chen XP, Xue YL, Li XJ, Zhang ZY, Li YL, Huang ZQ: Experimental research on TECA-I bioartificial liver support system to treat canines with acute liver failure. *World J Gastroenterol* 2001;7:706–709.
- 6 Michalopoulos GK, DeFrances MC: Liver regeneration. *Science* 1997;276:60–66.
- 7 Frühauf NR, Oldhafer KJ, Höltje M, Kaiser GM, Frühauf JH, Stavrou GA, Bader A, Broelsch CE: A bioartificial liver support system using primary hepatocytes: a preclinical study in a new porcine hepatectomy model. *Surgery* 2004;136:47–56.
- 8 Couinaud C: Lobes de segments hépatiques: notes sur l'architecture anatomique et chirurgicale du foie. *Presse Med* 1954;62:709–712.
- 9 Bismuth H, Dennison AR: Segmental liver resection. *Adv Surg* 1993;26:189–208.
- 10 Kahn D, Hickmann R, Terblanche J, von Somogyi S: Partial hepatectomy and liver regeneration in pigs – the response to different resection sizes. *J Surg Res* 1988;45:176–180.
- 11 Ladurner R, Hochleitner B, Bodner G, Offner F, Klima G, Krismer A, Löckinger A, Margreiter R, Königsrainer A: Extended hepatic resection and portosystemic shunt in pigs: a model for experimental liver regeneration. *Unpubl data*.
- 12 Nordlinger B, Douvin D, Javaudin L, Bloch P, Aranda A, Bosch M, Huguet C: An experimental study of survival after two hours of normothermic hepatic ischemia. *Surg Gynecol Obstet* 1980;150:859–864.
- 13 Bismuth H, Castaing D, Garden OJ: Major hepatic resection under total vascular exclusion. *Ann Surg* 1989;210:13–19.
- 14 Court FG, Laws PE, Morison CP, Teague BD, Metcalfe MS, Wemyss-Holden SA, Dennison AR, Maddern GJ: Subtotal hepatectomy: a porcine model for the study of liver regeneration. *J Surg Res* 2004;116:181–186.
- 15 Van der Meer C, Ver der Kley GA, Valkenburg PW: Studies on the cause of death after permanent and temporary occlusion of the portal vein in rats. *Circ Shock* 1976;3:191–202.
- 16 Hardy KJ, Tancheiroen S, Shulkes A: Comparison of continuous versus intermittent ischaemia-reperfusion in liver resection in an experimental model. *Br J Surg* 1995;82:833–836.
- 17 Van Wagensveld BA, Van Gulik TM, Gelderblom HC, Scheepers JJG, Bosma A, Endert E, Gouma DJ: Prolonged continuous or intermittent vascular inflow occlusion during hemihepatectomy in pigs. *Ann Surg* 1999;3:376–384.
- 18 Van Gulik TM, Heijnen BHM: Experimental liver resection; in Köckerling F, Schwartz SI (eds): *Liver Surgery, Operative Techniques and Avoidance of Complication*. Heidelberg, Barth Verlag, 2001, pp 131–135.